

Extracorporeal Shockwave Treatment for Chronic Diabetic Foot Ulcers

Ching-Jen Wang, M.D.,^{*,1} Yur-Ren Kuo, M.D., Ph.D.,[†] Re-Wen Wu, M.D.,^{*} Rue-Tsuan Liu, M.D.,[‡]
Chi-Shiung Hsu, M.D.,^{*} Feng-Sheng Wang, Ph.D.,[§] and Kuender D. Yang, M.D.[§]

^{*}Department of Orthopedic Surgery, [†]Department of Plastic and Reconstructive Surgery, [‡]Department of Internal Medicine, and
[§]Department of Medical Research, Chang Gung Memorial Hospital-Kaohsiung Medical Center, Chang Gung University College of
Medicine, Taiwan

Submitted for publication November 4, 2007

Background. This prospective study compared extracorporeal shockwave treatment (ESWT) with hyperbaric oxygen therapy (HBO) in chronic diabetic foot ulcers.

Patients and methods. Seventy-two patients with 72 chronic diabetic foot ulcers were randomly divided into two groups of similar demographics with 34 patients with 36 ulcers in the ESWT group and 36 patients with 36 ulcers in the HBO group. Patients in the ESWT group received 300 + 100/cm² impulses of shockwave at 0.11 mJ/cm² energy flux density every 2 wk for 6 wk, whereas patients in the HBO group received HBO daily for 20 treatments. The evaluations included clinical assessment of the ulcers with photo-documentation, blood flow perfusion scan, bacteriological examination, histological study, and immunohistochemical analysis.

Results. The overall results showed completely healed in 31%, improved in 58%, and unchanged in 11% for the ESWT group and 22% completely healed, 50% improved, and 28% unchanged for the HBO group. The ESWT group showed significantly better clinical results and local blood flow perfusion, higher cell concentration, and activity than the HBO group. On immunohistochemical analysis, the ESWT group demonstrated significant increases in endothelial nitric oxide synthase, vessel endothelial growth factor, and proliferation cell nuclear antigen expressions and a decrease in transference-mediated digoxigenin-deoxy-UTP nick end-labeling expression than the HBO group.

Conclusions. ESWT appears to be more effective than HBO in chronic diabetic foot ulcers. © 2008 Elsevier

Inc. All rights reserved.

Key Words: ESWT; HBO; diabetic; foot ulcers.

INTRODUCTION

Chronic diabetic foot ulcer is caused by small-vessel occlusion, usually compounded by neuropathy and infection [1–6]. Despite the changes in guidelines and classification, the treatment of a diabetic foot ulcer remains challenging and controversial [7–12]. Angioplasty or bypass surgery is generally ineffective in small-vessel disease and amputation becomes inevitable due to persistent critical limb ischemia, soft-tissue infection, and impaired wound healing with osteomyelitis [13, 14]. Skin grafts with different techniques are performed with the intention to heal the ulcers in selected cases [15]. Many adjunctive therapies are designed for the care of chronic diabetic foot ulcers including hyperbaric oxygen therapy (HBO), ultrasound, recombinant human platelet-derived growth factor-BB, vacuum-assisted wound closure, and acellular matrix with HBO being the most commonly used [13, 16–22]. The results of different treatment regimens of surgical and nonsurgical are inconsistent, and most studies reported limited success in selected series [19–23]. Therefore, the development of a new effective and noninvasive method of treatment for chronic diabetic foot ulcer is extremely valuable.

Recently, extracorporeal shockwave treatment (ESWT) was introduced for the treatment of chronic refractory diabetic and nondiabetic skin ulcers, and acute and chronic soft-tissue wounds with encouraging early results in short-term follow-up [24–27]. The purpose of this study was to evaluate the efficacy of ESWT in the treatment of chronic diabetic foot ulcers and to com-

¹ To whom correspondence and reprint requests should be addressed at Department of Orthopaedic Surgery, Chang Gung Memorial Hospital-Kaohsiung Medical Center, 123 Ta-Pei Road, Niao-Sung Hsiang, Kaohsiung, Taiwan 833. E-mail: w281211@cgmh.org.tw.

pare the results with that of HBO and to investigate the regeneration effects with local blood flow perfusion, histomorphological examination, and immunohistochemical analysis.

PATIENTS AND METHODS

The Institutional Review Board on Human Studies of our hospital approved this study. The declaration of Helsinki protocols were followed, and patients gave their written informed consent prior to participation in the study. The inclusion criteria included patients with recurrent chronic diabetic ulcers of the foot for more than 3 mo duration. Patients with deep wound sepsis or gangrenous changes usually required surgical debridement and wound care until the ulcers became stable but nonhealing prior to ESWT. Patients with quiescent osteomyelitis without recurrent symptoms for longer than 1 y were not excluded. The exclusion criteria include patients with cardiac arrhythmia or pacemaker, pregnancy, skeletal immaturity, patients with malignancy, and patients with poor compliance. Between August 2006 and January 2007, 74 patients with 76 chronic diabetic skin ulcers of the foot were enrolled in this study. Patients were randomly divided into two groups according to the dates of treatment. Thirty-six patients with 38 ulcers were referred on odd days of the week and received shockwave treatment, whereas 38 patients with 38 ulcers were referred on even days of the week and received HBO therapy. During the course of treatment, four patients with four ulcers were excluded because of poor compliance including two patients with two ulcers in ESWT group and two patients with two ulcers in the HBO group. The remaining 70 patients with 72 ulcers (34 patients with 36 ulcers in the ESWT group and 36 patients with 36 ulcers in the HBO group) completed the analysis. The flow diagram of patient recruitment is shown in Fig. 1. The patient demographic characteristics are summarized in Table 1.

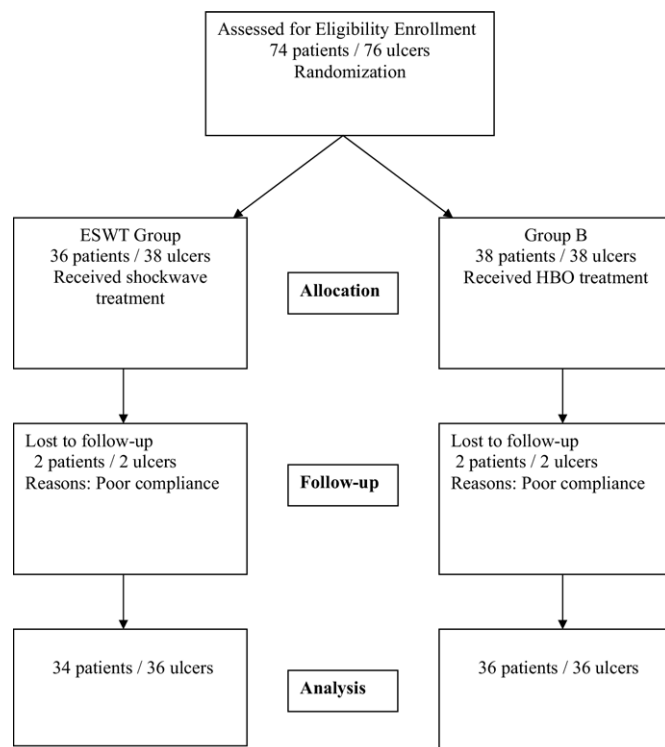


FIG. 1. Flow diagram of patient recruitment.

TABLE 1

Patient Demographic Characteristics

	ESWT	HBO	P value
No. patients/ulcers	34/36	36/36	0.865
Average age (y)	58.6 ± 12.6	63.4 ± 10.3	0.072
(range)	(33–79)	(39–81)	
Average size (cm ²)	11.2 ± 20.0	10.5 ± 20.0	0.478
(range)	(1.5–84)	(1.0–100)	
Average duration (mo)	22.7 ± 20.9	19.0 ± 19.5	0.306
Right/left	19/17	16/20	0.479
Location of ulcer			
Dorsal	23	17	0.155
Plantar	13	19	
Ave. HBA1c	9.08 ± 1.21	8.84 ± 2.11	0.326
(range)	(7.2–11.5)	(6.0–14.2)	
Ave. ABI	1.22 ± 0.19	1.26 ± 0.27	0.345
(range)	(1.10–1.62)	(1.02–2.11)	
Average follow-up (mo)	11.64 ± 2.15	12.14 ± 2.11	0.161
(range)	(6–14)	(6–14)	

ABI = Ankle brachial pressure index.

Pretreatment evaluations included complete history and physical examination, chemistry and coagulation profiles, the details of past surgical and medical treatments, including HBA1c data for blood sugar control. The circulatory status of the affected limb was evaluated with ankle-brachial pressure index using Doppler scan. The skin sensitivity was evaluated with a monofilament pinprick test. The dimension and depth and the appearance of the skin ulcer were quantitatively assessed clinically with photo-documentation of the ulcers in all cases. Local blood flow was checked with laser Doppler perfusion scan. Biopsy was performed from the most contaminated area of the ulcer. Culture and sensitivity was obtained from the biopsy specimens. The referring endocrinologist monitored the blood sugar level closely. The clinical assessment, local blood flow perfusion, culture and sensitivity, and biopsy of the ulcer were performed before and after treatment.

Shockwave Application

The source of ESWT was from an Orthowave 180 (MTS, Konstanz, Germany). The treatment was performed as outpatient under no anesthesia. The ulcer was covered with sterile cellulose barrier. The ultrasound gel was applied to the area of skin in contact with the shockwave tube. The treatment started out with a slow delivery of the shockwave impulses until the patient got accustomed to the nature of treatment. The protocol of shockwave application was 300 + 100/cm² impulses of shockwave at 0.11 mJ/cm² energy flux density evenly applied to the ulcer surface once every 2 wk for a total of three treatments in 6 wk. A repeat course of treatment was performed in cases with incomplete healing from the first course of treatment. Patients resumed the same wound care technique at home after treatment including off loading on the affected leg, wound cleansing with sterile normal saline solution, and application of silver sulfadiazine cream. No additional systemic or local antibiotic was prescribed.

Hyperbaric Oxygen Therapy

HBO was performed with patients in a sealed multi-place chamber at a pressure of 2.5 atmospheres absolute (ATA). The air pressure was gradually increased from 1 to 2.5 ATA in 15 min. Oxygen of 100% medical grade was inhaled through a plastic facemask for 25 min with a 5-min break in between for a total of 90 min per treatment. The air pressure was then decompressed from 2.5 ATA down

TABLE 2**The Overall Clinical Results After Treatment**

	ESWT	HBO	<i>P</i> value
No. patients/ulcers	34/36	36/36	
Completely healed	31% (11/36)	22% (8/36)	0.001
≥50% improved	58% (21/36)	50% (18/36)	
Unchanged	11% (4/36)	28% (10/36)	

to 1.0 ATA within 15 min to complete the treatment. HBO was performed once a day, 5 times a wk for a total of 20 treatments. Patients received the same wound care as the ESWT group.

Four patients (three in the ESWT group and one in the HBO group) underwent surgical debridement for deep wound sepsis, necrosis, and extensive keratosis surrounding the ulcer, and received wound care until the ulcers became stable but nonhealing, prior to receiving the respective treatment.

Evaluation Parameters

The follow-up evaluations were scheduled at 2, 4, and 6 wk, then once every 3 mo. The evaluation parameters included clinical assessment of the ulcer status with photo-documentation, bacterial colony count, and type of microorganisms, histomorphological examination, and immunohistochemical analysis.

Clinical Assessment

The size and depth of the ulcers, local sepsis, arteriopathy, and neuropathy were carefully assessed before treatment and at different time intervals after treatment. The extent of wound healing with epithelization at different time intervals was documented with visual examination and photographs of the ulcer.

Bacteriological Examination

The types of microorganisms and the amounts of bacteria growth were determined from the results of culture of the ulcer. The culture

specimens were placed on the test media in sterile culture dishes containing blood agar and normal saline and 95% alcohol. The cultures were performed in eight plastic tubes on a test tube rack with graduated dilutions of blood agar and normal saline and were stored in a 35°C 5% CO₂ incubator for 16 to 18 h. The culture results identified the presence or absence of any microorganisms and measured the colony forming units. The bacteria colony counts were based on the numbers of the colony in the plastic tube with the most diluted culture media and were graded 0 for no growth, I for rare growth, II for light growth, III for moderate growth, and VI for heavy growth.

Histomorphological Examination

The histomorphological features of the biopsy specimens including tissue distribution, cell concentration, cell activity, and proliferation were examined microscopically with hematoxylin-eosin stain before and after treatment.

Immunohistochemical Analysis

Sections of the biopsy specimen were immunostained with the specific reagents to identify the angiogenesis-related growth and proliferating indicators including endothelial nitric oxide synthase (eNOS), vessel endothelial growth factor (VEGF), proliferation cell nuclear antigen (PCNA), and transference-mediated digoxigenin-deoxy-UTP nick end-labeling (TUNEL) (Santa Cruz Biotechnology Inc., Santa Cruz, CA). The immunoreactivity in specimens was demonstrated using a horseradish peroxidase 3',3'-diaminobenzidine cell and tissue staining kit (R&D Systems, Inc., Minneapolis, MN). The immuno-activities were quantified from five areas in three sections of the same specimen using a Zeiss Axioskop 2 plus microscope (Carl Zeiss, Gottingen, Germany). All of the images of each specimen were captured using a Cool CCD camera (SNAP-Pro *c.f.* Digital kit; Media Cybernetics, Silver Spring, MD). Images were analyzed using an Image-Pro® Plus image-analysis software (Media Cybernetics). The percentage of positive immuno-labeled cells over the total cells in each area was counted. Two pathologists blinded to the treatment regimen performed the measurements on all sections.

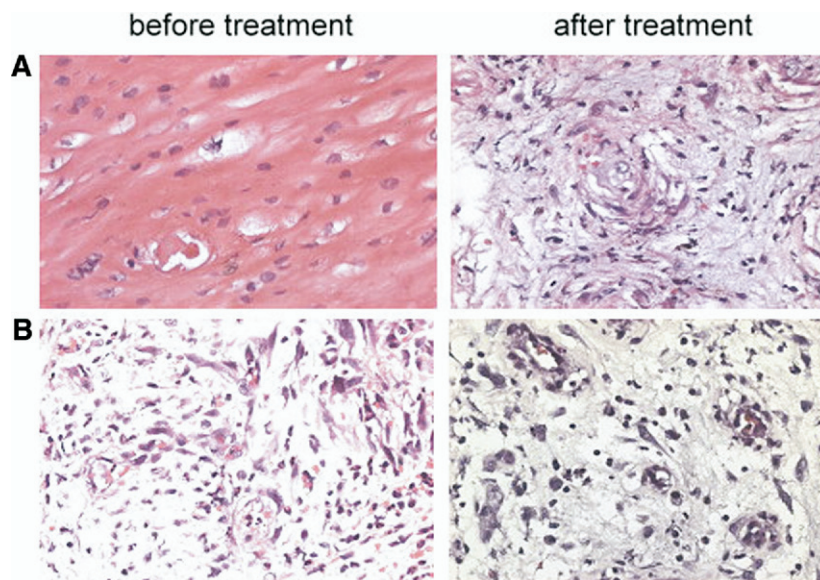


FIG. 2. Microscopic features of the biopsy specimen showed higher cell concentration and more cell proliferation after ESWT (A), and less cell concentration and proliferation after HBO (B) (Hematoxylin-eosin stain, ×40).

TABLE 3

The Results of Bacteriological Examination

Bacterial growth*	0	I	II	III	VI	P value†
ESWT group						
Before treatment	4	3	9	17	3	0.002
After treatment	13	4	11	8	0	
HBO group						
Before treatment	5	3	9	15	4	0.042
After treatment	11	0	12	12	1	
P value‡						0.984
P value§						0.198

* 0: No bacterial growth; I: rare growth; II: light growth; III: moderate growth; VI: heavy growth.

† P value: Comparison of data before and after treatment within the same group.

‡ P value: Comparison of data between the two groups before treatment.

§ P value: Comparison of data between the two groups after treatment.

Blood Flow Test

The tissue viability was measured with local blood flow perfusion scan. The local blood flow perfusion was measured using the Peri-Scan PIM II Laser Doppler Perfusion Imager (Perimed AB, Stockholm, Sweden). The object was placed on a light absorbing background material such as a black or a dark green cloth. The distance between the scanner head and the object is 15 cm. The Min and Max values were set at 0 and 5 V, respectively. The perfusion scan image color scale displayed the lowest value in dark blue and the highest value in dark red. LDPIwin software in Window 95/98/2000 was used for data analysis including the minimal value, the maximal value, and the mean and standard deviation.

Statistical Analysis

A power analysis revealed that a sample size of 23 would be required to establish the statistical significance with $\alpha = 0.05$ and

power = 0.8. The data before and after treatment within the same group were compared statistically using a paired *t*-test. The overall results between the ESWT group and the HBO group were compared statistically using the χ^2 test. The statistical significance was set at $P < 0.05$.

RESULTS

The overall results of treatment are summarized in Table 2. The results showed completely healed in 31%, improved in 58%, and unchanged in 11% for the ESWT group and 22% completely healed, 50% improved, and 28% unchanged for the HBO group ($P < 0.001$). More than 50% improvement of the ulcer was observed in 89% of ESWT group and 72% of HBO group ($P < 0.001$). ESWT appears to be more effective than HBO in the treatment of diabetic foot ulcers.

In histomorphological examination, the microscopic features of the biopsy specimens revealed higher cell concentration and more cell proliferation and activity after ESWT than after HBO (Fig. 2).

The results of bacteriological examination are summarized in Table 3. Both ESWT and HBO groups showed a bacteriostatic effect; however, no significant difference was noted between the two groups. None showed exacerbation of infection after treatment.

The results of immunohistochemical stain are summarized in Table 4. The differences in the increases of eNOS, VEGF, and PCNA expressions and the decrease of TUNEL expression between the two groups were statistically not significant before treatment ($P > 0.05$). However, such differences became statistically significant after treatment ($P < 0.05$). The ESWT group showed significant increases in eNOS, VEGF, and PCNA expressions and a trend of decreases in

TABLE 4

The Results of Immunohistochemical Analysis

Mean \pm SD (range)	Before treatment	After treatment	P value*
eNOS			
ESWT	26.62 \pm 14.87 (4–57)	48.67 \pm 18.82 (6–72)	0.317
HBO	25.2 \pm 17.09 (6–53)	20.08 \pm 9.73 (6–30)	
P value†	0.438	<0.001	
VEGF			
ESWT	31.36 \pm 22.27 (8–90)	63.69 \pm 21.06 (25–91)	0.409
HBO	42.6 \pm 12.6 (28–55)	44.40 \pm 11.24 (30–56)	
P value†	0.086	0.042	
PCNA			
ESWT	27.0 \pm 15.15 (7–53)	55.9 \pm 27.86 (8–95)	0.064
HBO	23.0 \pm 2.83 (20–26)	26.20 \pm 3.11 (23–30)	
P value†	0.188	0.004	
TUNEL			
ESWT	62.42 \pm 15.0 (39–82)	31.58 \pm 13.44 (14–56)	0.162
HBO	64.0 \pm 25.58 (23–86)	49.4 \pm 17.0 (22–65)	
P value†	0.451	0.04	

eNOS = endothelial nitric oxide synthase; VEGF = vessel endothelial growth factor; PCNA = proliferation cell nuclear antigen; TUNEL = transference-mediated digoxigenin-deoxy-UTP nick end-labeling.

* P value: comparison of data before and after treatment within the same group.

† P value: comparison of data between ESWT and HBO.

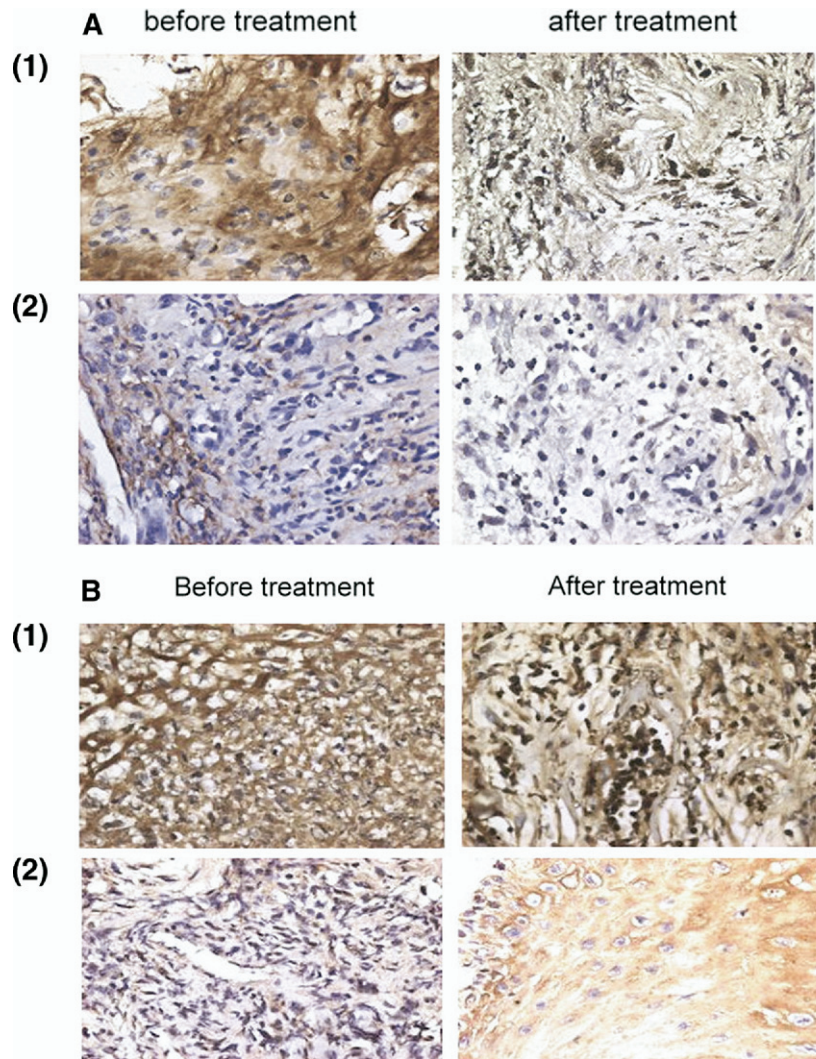


FIG. 3. (A) Microscopic features of immunohistochemical stain showed significant increase in eNOS expression after ESWT (A1), whereas the changes were not significant after HBO (A2). (B) Microscopic features of immunohistochemical stain showed significant increase in VEGF expression after ESWT (B1), whereas the changes were not significant after HBO (B2). (C) Microscopic features of immunohistochemical stain showed significant increase in PCNA expression after ESWT (C1), whereas the changes were not significant after HBO (C2). (D) Microscopic features of immunohistochemical stain revealed significant decrease in TUNEL expression after ESWT (D1), whereas the changes were not significant after HBO (D2).

TUNEL expression after treatment ($P < 0.05$), whereas the changes in the HBO were statistically not significant ($P > 0.05$). The microscopic features are shown in Fig. 3A–D. It appears that application of ESWT results in increased angiogenesis and cell activities and decreased cell apoptosis as compared with HBO.

The results of blood flow perfusion based on laser Doppler scan are summarized in Table 5. Significant improvement in local blood flow perfusion scan was noted after ESWT ($P = 0.04$), but not after HBO ($P = 0.140$). The differences in local blood flow perfusion

between the two groups were statistically not significant before treatment ($P = 0.30$); however, such differences became statistically significant after treatment, favoring the ESWT group ($P = 0.043$). The perfusion scans are shown in Fig. 4.

DISCUSSION

The causes of diabetic foot ulcers are multifactorial, including ischemia, hypoxia, neuropathy, and infection, and they often coexist [3–5, 14, 28]. The management of chronic diabetic foot ulcers require mul-

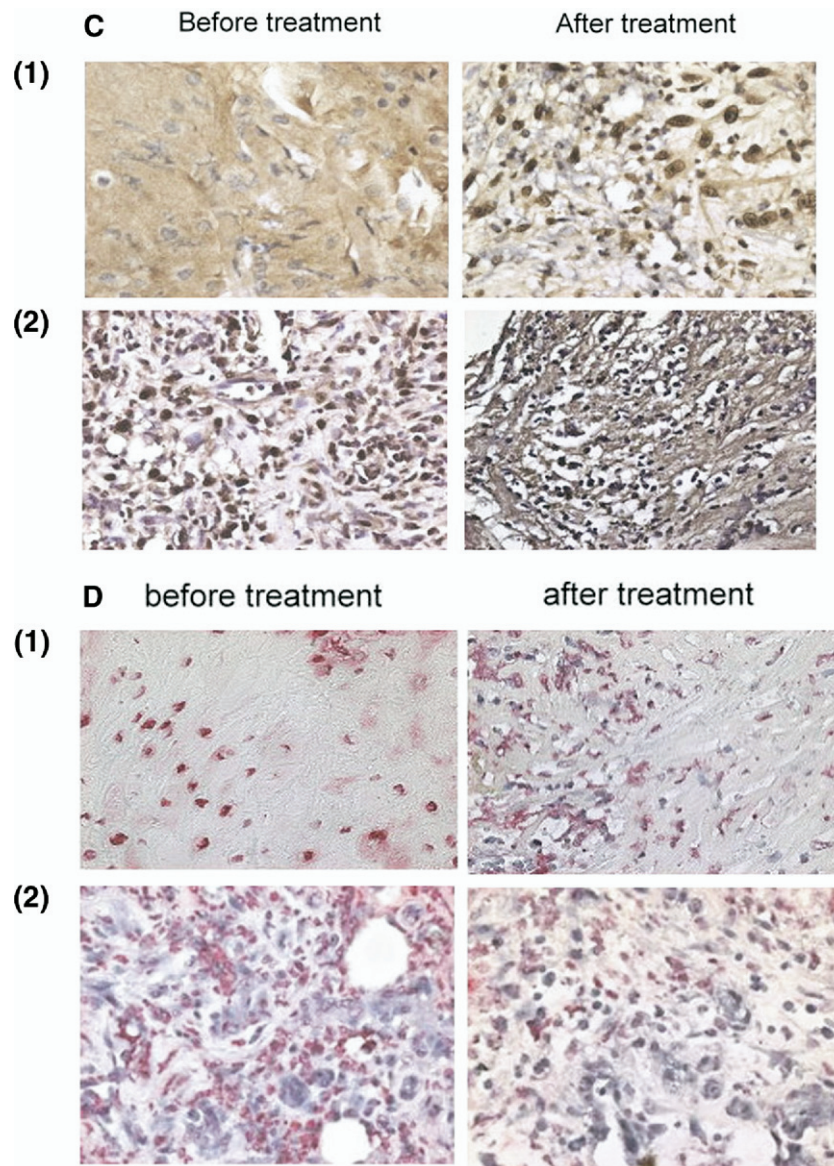


FIG. 3—Continued

tidisciplinary approaches including control of blood sugar, antibiotics, shoe wear, wound care, and surgery in selected cases with the primary goal to control the diabetic mellitus and to avoid complications [2–5, 19, 28]. In some cases, amputation becomes inevitable due to gangrene and/or infection [2–5, 28]. Many patients present with recurrent refractory chronic foot ulcers that respond inconsistently to various surgical or nonsurgical treatments. Therefore, chronic diabetic foot ulcer remains as an unresolved medical entity.

Many studies used different adjunctive therapies with the intention to cure the diabetic skin ulcers in-

cluding HBO [13, 18, 20, 29], ultrasound [1], recombinant platelet-derived growth factor-BB [22], vacuum-assisted wound closure [17, 21], and acellular matrix [16]. Among them, HBO is the most commonly used modality at our institution. HBO is a controversial treatment in chronic diabetic foot ulcers. Many studies reported positive effects of HBO in chronic diabetic foot ulcers [5, 13, 18–20], whereas other studies reported HBO to have little to no credible evidence for its effectiveness in chronic diabetic foot ulcers [23]. The successful clinical results were reported ranging from 22 to 89% and most studies showed less than satisfactory results [5, 13, 19]. The results of the current study

showed that HBO is not nearly as effective as ESWT in chronic diabetic foot ulcers.

The exact mechanism of ESWT remains unclear. Some studies showed dose-related effects of ESWT that relieves pain with decreased nonvascular substance P positive sensory nerve fibers and calcitonin gene-related peptide [30–32]. Other studies demonstrated that ESWT acts as mechanotransduction that induces the ingrowth of neovascularization associated with increased expressions of angiogenesis-related growth and proliferation factors (eNOS, VEGF, and PCNA) leading to tissue regeneration [33–35]. The results of the current study showed that ESWT is more effective than HBO in chronic diabetic foot ulcer. Furthermore, clinical improvements of the ulcers were associated with increased local blood flow perfusion and angiogenesis and a trend of decrease in cell apoptosis. In addition, both ESWT and HBO showed bacteriostatic effects with no difference between the two groups. Overall, these findings strongly suggested that application of ESWT results in tissue regeneration.

There are limitations in this study. This study is limited by virtue of the small number of patients creating a relatively low power of statistics. The follow-up time is short. The long-term results of ESWT in chronic diabetic ulcers are unknown from the current study. Further, no standard therapy group was used as control in this study, although our patients could be regarded as the control as they all failed with standard therapy. For tissue viability, neither the direct methods of measurement including fluorescent angiography, thermograph, and radionuclide clearance techniques, nor the indirect methods such as transcutaneous tissue O_2 and direct O_2 saturation measurements were performed. In this study, local blood flow perfusion scan was used instead.

In conclusion, ESWT appears to be more effective than HBO in the treatment of chronic diabetic foot ulcers. Application ESWT results in tissue regenera-

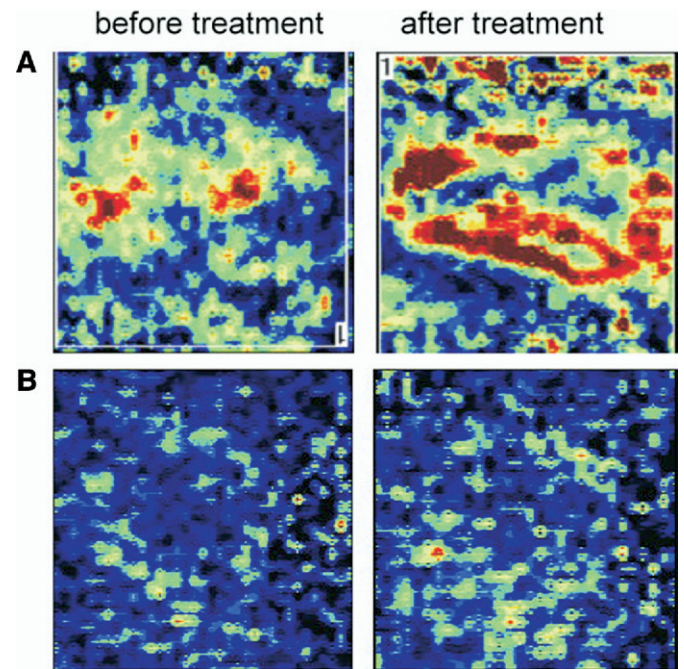


FIG. 4. Laser Doppler scan showed significant increase in blood flow perfusion after ESWT (A), whereas the changes were not significant after HBO (B).

tion that ultimately heals the ulcers. ESWT is a new, effective, and safe adjunctive therapy in chronic diabetic foot ulcers.

ACKNOWLEDGMENTS

Funds were received in total or partial support for the research or clinical study presented in this article. The funding sources were from the National Science Council (95-2314-B-182A-081), Tissue Regeneration Technologies, and National Health Research Institute (NHRI-EX96-9423EP).

REFERENCES

1. Ennis WJ, Foremann P, Mozen N, et al. Ultrasound therapy for recalcitrant diabetic foot ulcers: Results of a randomized, double-blind controlled, multicenter study. *Ostomy Wound Manage* 2005;51:24.
2. Jeffcoate WJ, Harding KG. Diabetic foot ulcers. *Lancet* 2003; 361:1545.
3. Macfarlane RM, Jeffcoate WJ. Factors contributing to the presentation of diabetic foot ulcers. *Diabet Med* 1997;14:867.
4. Mason J, O'Keeffe C, Hutchinson A, et al. A systematic review of foot ulcer in patients with type 2 diabetes mellitus. II, treatment. *Diabet Med* 1999;16:889.
5. O'Meara S, Cullum N, Majid M, et al. Systematic reviews of wound care management; (3) anti-microbial agents for chronic wounds; (4) diabetic foot ulceration. *Health Technol Assess* 2000;4:1.
6. Perkins BA, Zinman B, Olaleye D, et al. Simple screening tests for peripheral neuropathy in the diabetes clinic. *Diabetes Care* 2001;24:250.

TABLE 5

Blood Flow Perfusion Before and After Treatment

Laser Doppler	Before treatment	After treatment	<i>P</i> value*
ESWT			
Mean \pm SD	0.64 \pm 0.28	0.75 \pm 0.19	0.04
(Range)	(0.19–1.23)	(0.46–1.28)	
HBO			
Mean \pm SD	0.50 \pm 0.21	0.58 \pm 0.11	0.140
(Range)	(0.18–0.6)	(0.51–0.66)	
<i>P</i> value†	0.30	0.043	

* *P* value: Comparison of data before and after treatment within the same group.

† *P* value: Comparison of data between ESWT and HBO.

7. Armstrong DG, Lavery LA, Harkless LB. Validation of a diabetic wound classification system. *Diabetes Care* 1998;21:855.
8. Jeffcoate WJ, Macfarlane RM, Fletcher EM. The description and classification of diabetic foot lesions. *Diabet Med* 1993;10:676.
9. Lavery LA, Armstrong DG, Harkless LB. Classification of diabetic foot wounds. *J Foot Ankle Surg* 1996;35:528.
10. Macfarlane RM, Jeffcoate WJ. Classification of diabetic foot ulcers: The S (AD) SAD system. *Diabetic Foot* 1999;2:123.
11. Schaper NC, Apelqvist J, Bakker K. The international consensus and practical guidelines on the management and prevention of the diabetic foot. *Current Diabetes Rep* 2003;3:475.
12. Treece KA, Macfarlane RM, Pound N, et al. Validation of a system of foot ulcer classification in diabetes mellitus. *Diabet Med* 2004;21:987.
13. Unger HD, Lucca M. The role of hyperbaric oxygen therapy in the treatment of diabetic foot ulcers and refractory osteomyelitis. *Clin Podiatr Med Surg* 1990;7:483.
14. Venkatesan P, Lawn S, Macfarlane RM, et al. Conservative management of osteomyelitis in the feet of diabetic patients. *Diabet Med* 1997;14:487.
15. Ruffieux P, Hommel L, Saurat JH. Long-term assessment of chronic leg ulcer treatment by autologous skin grafts. *Dermatology* 1997;195:77.
16. Bigido SA, Boc SF, Lopez RC. Effective management of major lower extremity wounds using an acellular regenerative tissue matrix: A pilot study. *Orthopedics* 2004;27(1 Suppl):s145.
17. Enton MT, Brown KR, Seabrook GR, et al. A prospective randomized evaluation of negative-pressure wound dressings for diabetic foot wounds. *Ann Vasc Surg* 2003;17:645.
18. Faglia E, Favales F, Aldeghi A, et al. Adjunctive systemic hyperbaric oxygen therapy in treatment of severe prevalently ischemic foot ulcers. *Diabetic Care* 1996;19:1338.
19. Kranke P, Bennett M, Roeckl-Wiedmann I, et al. Hyperbaric oxygen therapy for chronic wounds. *Cochrane Database System Rev* 2004;CD004123.
20. Londahl M, Katzman P, Nilsson A, et al. A prospective study: Hyperbaric oxygen therapy in diabetics with chronic foot ulcers. *J Wound Care* 2006;15:457.
21. Mlner T, Mrkonjic L, Kwasny O, et al. The use of negative pressure to promote the healing of tissue defects: A clinical trial using vacuum sealing technique. *Br J Plast Surg* 1997;50:194.
22. Robson MC, Phillips LG, Thomason A, et al. Recombinant human platelet-derived growth factor-BB for the treatment of chronic pressure ulcers. *Ann Plast Surg* 1992;29:193.
23. Berendt AR. Counterpoint: Hyperbaric oxygen for diabetic foot wounds is not effective. *Clin Infect Dis* 2006;43:193.
24. Elster EA, Davis TA, Stojadinovic A. Combat wound initiative summary. P. 56, the 10th Congress of International Society for Musculoskeletal Shockwave Therapy (ISMST) June 6–9 2007 Abstr, Toronto, Canada.
25. Pusch M, Köpl C, Valentin A, et al. Extracorporeal shockwave therapy for chronic skin lesions. P. 55, the 10th Congress of International Society for Musculoskeletal Shockwave Therapy (ISMST) June 6–9, 2007 Abstr, Toronto, Canada.
26. Santos PR, Guedes M, Guimaraes L, et al. Extracorporeal shockwave therapy for chronic skin ulcers in diabetic patients. P. 52, the 10th Congress of International Society for Musculoskeletal Shockwave Therapy (ISMST) June 6–9, 2007 Abstr, Toronto, Canada.
27. Schaden W, Thiele R, Kolpl C, et al. Shock wave therapy for acute and chronic soft tissue wounds. A feasibility study. *J Surg Res* 2007;143:1.
28. Johnstone MT, Creager SJ, Scales KM, et al. Impaired endothelium-dependent vasodilatation in patients with insulin-dependent diabetes mellitus. *Circulation* 1993;88:2510.
29. Niinikoski J. Hyperbaric oxygen therapy of diabetic foot ulcers, transcutaneous oxymetry in clinical decision-making. *Wound Repair Regen* 2003;11:458.
30. Maier M, Averbek B, Milz S, et al. Substance P and prostaglandin E2 release after shockwave application to the rabbit femur. *Clin Orthop Rel Res* 2003;406:237.
31. Ohtori S, Inoue G, Mannoji C, et al. Shockwave application to rat skin induces degeneration and reinnervation of sensory nerve fibers. *Neurosci Lett* 2001;315:57.
32. Rompe JD, Kirkpatrick CJ, Kullmer K, et al. Dose-related effects of shock waves on rabbit tendo Achillis. A sonographic and histological study. *J Bone Joint Surg Br* 1998;80:546.
33. Wang CJ, Huang HY, Pai CH. Shock wave enhances neovascularization at the tendon-bone junction. *J Foot Ankle Surg* 2002;41:16.
34. Wang CJ, Yang K, Wang FS, et al. Shock wave induces neovascularization at the tendon-bone junction. A study in rabbits. *J Orthop Res* 2003;21:984.
35. Wang FS, Wang CJ, Chen YJ, et al. Ras induction of superoxide activates ERK-dependent angiogenic transcription factor HIF-1 α and VEGF-A expression in shock wave-stimulated osteoblasts. *J Biol Chem* 2004;279:10331.